

# Primary Prostate Tuberculosis: A Cause of Raised Prostate Specific Antigen (PSA)

OP Oluwhole<sup>1</sup>, OI Aisuodionoe-Shadrach<sup>2</sup>, HO Ajibola<sup>2</sup>, A Atim<sup>2</sup>

<sup>1</sup> Department of Pathology/Forensic Medicine, University of Abuja Teaching Hospital, Gwagwalada, Abuja, F.C.T, Nigeria.

<sup>2</sup> Division of Urology, Department of Surgery, University of Abuja Teaching Hospital, Gwagwalada, Abuja, F.C.T, Nigeria.

**How to cite this paper:** OP Oluwhole, OI Aisuodionoe-Shadrach, HO Ajibola, A Atim. (2019) Primary Prostate Tuberculosis: A Cause of Raised Prostate Specific Antigen (PSA). *International Journal of Clinical and Experimental Medicine Research*, 3(1), 93-96.

DOI: 10.26855/ijcemr.2019.01.001

**\*Corresponding author:** OP Oluwhole, Department of Pathology/Forensic Medicine, University of Abuja Teaching Hospital, Gwagwalada, Abuja, F.C.T, Nigeria.

Email: peter.olabode@uniabuja.edu.ng

---

## Abstract

**Background:** The prostate is one of the most common sites for cancer and in contrast prostate tuberculosis seems to be a rare disease. Mycobacterium tuberculosis and cancer look like antagonists; based on this principle BCG-therapy for bladder cancer was established.

**Materials and Methods:** A retrospective study of primary tuberculosis diagnosed between January to December 2015 was conducted in the Department of Pathology/Forensic Medicine, University of Abuja Teaching Hospital, Gwagwalada, Abuja. The materials consisted of tissue blocks, glass slides and duplicates histopathology reports of patients whose specimens were received and processed in the Histopathology Laboratory of the hospital. The slides were reviewed blinded by two consultant pathologists. The variables looked at were age of the patients, consistency of the prostate and histological diagnosis. Informed consent was obtained from the patients and University of Abuja Teaching Hospital IRB (NHREC/12/12/2008a) was obtained for the study.

**Results:** Three primary tuberculosis of the prostate was studied on trucut sextant biopsy. The age range of the patients was between 55-74 years. All the three patients were found to have an enlarged hard prostate gland with raised PSA levels ranging from 9-15ng/ml; none of the patients has had history of contact with chronic tuberculosis patients in the remote past. The working diagnosis of the urologist was prostate cancer but their histopathology results came out to be primary tuberculosis of the prostate.

**Conclusion:** Although, primary prostatic tuberculosis is a rare disease and a great mimic of prostate cancer, however, with a high index of suspicion and diligent search, it can be diagnosed on histopathology. Once diagnosis has been established a good outcome can be achieved with anti-tuberculosis drugs.

## Keywords

Primary Tuberculosis, High index of suspicion, Use of anti-tuberculosis therapy

---

## Introduction

The World Health Organization (WHO) recognizes tuberculosis (TB) as a global problem. In 2013, an estimated 9.0 million people developed TB and 1.5 million died from the disease, 360,000 of whom were Human Immunodeficiency Virus (HIV) – positive [1].

Tuberculosis is endemic in Nigeria which rank 10<sup>th</sup> among the twenty-two highest tuberculosis burdened countries of the world; the second highest in Africa [2]. Tuberculosis of the prostate accounts for 2.3% of urogenital tuberculosis in Nigeria [3]. Urogenital tuberculosis is the second most common form of extra-pulmonary tuberculosis after lymph node involvement in countries with severe epidemics [4].

Although, tuberculosis of the prostate is very rare, and co-existence of adenocarcinoma and genitourinary tuberculosis

frequently seen, their concomitance is extremely rare [5,6].

However, a recent study has shown that chronic prostate inflammation accelerates prostate cancer progression [7], promotes initiation of diverse malignancies, enhances basal-to-luminal differentiation, and accelerates initiation of prostate cancer originating in the basal cells [8,9].

## Materials and Methods

A retrospective study of primary tuberculosis diagnosed between January to December 2015 in the Department of Pathology/Forensic Medicine, University of Abuja Teaching Hospital, Gwagwalada, Abuja. The materials consisted of tissue blocks, glass slides and duplicates histopathology reports of patients whose specimens were received and processed in the Histopathology Laboratory of the hospital. The slides were reviewed blinded by two consultant pathologists.

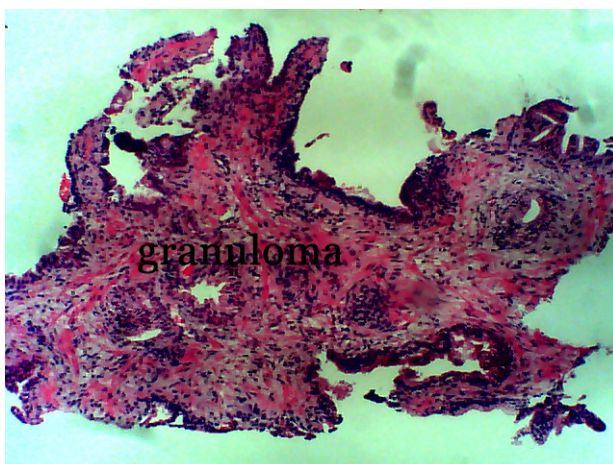
## Results

Three primary tuberculosis of the prostate was studied on trucut sextant biopsy. The age range of the patients was between 55-74 years. All the three patients were found to have an enlarged hard prostate gland with raised PSA levels ranging from 9-15ng/ml; none of the patients has had history of contact with chronic tuberculosis patients in the remote past. The working diagnosis of the urologist was prostate cancer.

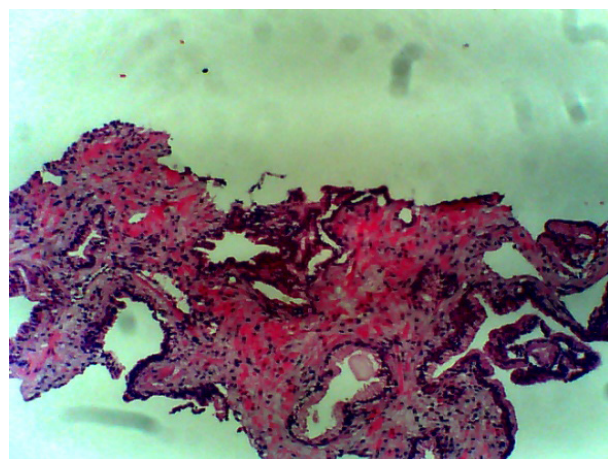
On gross examination, we received prostatic cores whose measurement ranges from 20x5x3mm to 15x3x2mm to 10x3x2mm respectively. The microscopic examination showed multiple granulomata in a background mixed inflammatory infiltrates comprising lymphocytes, plasma cells and few eosinophils. The granuloma is composed of epithelioid cells, Langhans and foreign body giant cells, reactive small and large reactive lymphocytes, plasma cells and fibrous tissue. Other areas revealed nodular hyperplasia with dilated glands containing corpora amylacea, no evidence of malignancy seen.

A diagnosis of primary tuberculosis of the prostate was made. (Figure 1)

The patients were commenced on six months' direct observatory therapy (DOT) course of anti-TB drugs. On completion of treatment, the patients had complete resolution of symptoms and PSA reverting to the range of 2.6ng/ml post-treatment and repeat prostate biopsy revealed healed tubercles. (Figure 2)



**Figure 1:** Prostatic biopsy showing two central granulomata in a background of mononuclear cells. X100.



**Figure 2:** Prostatic biopsy showing areas of healed tubercles and hyalinized fibrosis after treatment with anti-TB drugs. X100.

## Discussion

Tuberculosis (TB) remains a major public health problem in developing countries [1]. Involvement of the prostate gland is very rare, but can occur either in isolation [10], with other genitourinary organs like epididymis and seminal vesicle, or as part of a disseminated tuberculosis [11].

Autopsy reports however showed that it may not be as rare as reported as a result of under-reporting or generally under-diagnosis [3,12].

Prostate TB is caused by mycobacterium tuberculosis usually from haematogenous spread but rarely by descending infection

from urinary tract and results in chronic granulomatous inflammation of the prostate resulting in caseation necrosis that either heals by fibrosis or causes cavitation's or sloughing [13, 14]. Development of a so-called watering can perineum, secondary to multiple tuberculous fistulae in the perineum, has been reported as well [15].

Prostate TB has no pathognomonic clinical features. Initially, patients are asymptomatic or may present with non-specific irritative lower urinary tract symptoms (LUTS) or haemospermia. Haemospermia gives a strong suspicion of tuberculous infection and its sequelae. Digital rectal examination (DRE) may reveal a non-tender, nodular, firm to hard and rarely enlarged prostate [16].

Tuberculosis involving the prostate may be very difficult to differentiate from the carcinoma of the prostate, particularly when the prostate is hard and nodular on digital rectal examination [17]. Prostate TB is mainly diagnosed incidentally, either following trucut needle biopsy of the prostate for a suspected carcinoma of the prostate [18] or after prostatectomy specimen for benign prostatic hyperplasia (BPH) is subjected to histology [19]. Very rarely prostate cancer can co-exist with TB of the prostate [5, 6].

In this study, the patients presented with irritative LUTS, associated with low grade pyrexia, anorexia, low back ache, weight loss, occasional lower limb weakness, drenching night sweat, but no history of chronic cough, contact with chronically coughing adult or ingestion of unpasteurized milk. This is similar to the findings reported by Aisuodionoe-Shadrach et al [20] and Aji et al [21] in their case reports.

Prostate TB may cause transient elevation of PSA levels that decreases with resolution of the chronic inflammation [22]. This was in our patients that has PSA levels that range between 9-15ng/ml. Similar range of PSA levels were reported Murugan et al [23], Kulchavenya et al [24] and Aisuodionoe-Shadrach et al [20] respectively. Although, the study by Murugan [23] and Kulchavenya [24] et al had associated prostatic adenocarcinoma in their reports.

Drugs remain the treatment of choice for prostatic tuberculosis. Patients in whom primary tuberculosis of the prostate was diagnosed after histopathological examination of a biopsy specimen often recover on anti-tuberculous therapy alone [15]. All the three patients were treated with DOT course of anti-TB drugs for six months, they all had complete resolution of the symptoms and all DRE signs reverting to normal.

In conclusion, tuberculosis of the prostate, though rare can mimic prostate cancer with raised PSA levels. A high index of both clinical and histopathologic suspicion is therefore need in order to avoid misdiagnosis particularly for those practicing in developing countries where tuberculosis is endemic.

## References

- [1] World Health Organization. (2014). *Global tuberculosis report 2014*. World Health Organization.
- [2] World Health Organization. (2012). *Global Tuberculosis Control 2012*. World Health Organization.
- [3] Orakwe, J. C., & Okafor, P. I. S. (2005). Genitourinary tuberculosis in Nigeria; a review of thirty-one cases. *Nigerian journal of clinical practice*, 8(2), 69-73.
- [4] Sharma, S. K., & Mohan, A. (2004). Extrapulmonary tuberculosis. *Indian Journal of Medical Research*, 120, 316-353.
- [5] Stay, E. J. (1980). Tuberculosis and adenocarcinoma of prostate gland. *Urology*, 16(4), 422-424.
- [6] Ventura, M. (1966). Unusual histological finding: carcinoma and primary tuberculosis of the prostate. *Minerva urologica*, 18(6), 208-212.
- [7] Simons, B. W., Durham, N. M., Bruno, T. C., Grosso, J. F., Schaeffer, A. J., Ross, A. E., ... & Schaeffer, E. M. (2015). A human prostatic bacterial isolate alters the prostatic microenvironment and accelerates prostate cancer progression. *The Journal of pathology*, 235(3), 478-489.
- [8] Kwon, O. J., Zhang, L., Ittmann, M. M., & Xin, L. (2014). Prostatic inflammation enhances basal-to-luminal differentiation and accelerates initiation of prostate cancer with a basal cell origin. *Proceedings of the National Academy of Sciences*, 111(5), E592-E600.
- [9] Liu, X., & Goldstein, A. S. (2014). Inflammation promotes prostate differentiation. *Proceedings of the National Academy of Sciences*, 111(5), 1666-1667.
- [10] Cradon, LRG. (1902). Tuberculosis of the prostate. *New England journal of Medicine*, 147, 17-19.
- [11] Mittel, R., & Veeraraghavam, S. M. (2010) Disseminated Tuberculosis with involvement of the prostate. A case report. *The Indian Journal of Tuberculosis*, 57(1), 364-369.
- [12] Merchant, S. A. (1993). Tuberculosis of the genitourinary system Part 2: Genital tract Tuberculosis. *Indian J Radial Imaging*, 3, 275-286.
- [13] Hemal, A. K., Aron, M., Nair, M., & Wadhwa, S. N. (1998). 'Autoprostatectomy': an unusual manifestation in genitourinary tuberculosis. *British journal of urology*, 82(1), 140-141.

- [14] Kulchavenya, E. (2010). Some aspects of urogenital tuberculosis. *Int J Nephrol Urol*, 2(1), 351-360.
- [15] Ratlal, J. M. (2015) Primary Tuberculosis of the prostatic tuberculosis: A rare form of genitourinary tuberculosis. *African Journal of Urology*, 21(2), 142-143.
- [16] Fujikawa, K., Matsui, Y., Fukuzawa, S., Soeda, A., & Takeuchi, H. (1999). A case of tuberculosis of the prostate. *Scandinavian journal of urology and nephrology*, 33(4), 268-269.
- [17] Huang, K., Wu, H., Hsu, Y., et al. (2001) Tuberculosis of the prostate. *Journal of Urology*, 12(3):10-13.
- [18] Klis, R., Mioczkowski, D., & Sosnowski, M. (2006) Tuberculosis of the prostate: Rare case report. *Urological polsa*, 1, 1-3.
- [19] Bhargava, N., & Bhargava, S. K. (2003). Primary tuberculosis of the prostate. *Indian journal of radiology and imaging*, 13(2), 236.
- [20] Aisuodionoe-Shadrach, O. I., Ajibola, H. O., & Oluwole, O. P. (2014) Tuberculosis of the prostate masquerading as prostate cancer in a 74 year old Nigeria. *New Nigerian Journal of Clinical Research*, 4(6), 451-454.
- [21] Aji, S. A., Alhassan, S. U., Mashi, S. A., & Imam, M. I. (2013). Tuberculosis of the Prostate Gland Masquerading Prostate Cancer: A Case Report. *Open Journal of Urology*, 3(07), 269.
- [22] Singh, J., Sharma, P., Vijay, M. K., Kundu, A. K., & Pal, D. K. (2013). Tuberculosis of the Prostate: Four Cases and a Review of the Literature. *UroToday Int J*, 6(1),1-3.
- [23] Murugan, P., Brown, R. E., & Zhao, B. (2010). Nonspecific granulomatous prostatitis with prostatic adenocarcinoma. *Indian Journal of Pathology and Microbiology*, 53(1), 152.
- [24] Kulchavenya, E., & Kholtohin, D. (2015). Prostate Tuberculosis as predisposition for Prostate Cancer. *Clin Res Infect Dis*, 2(1), 1014.